



# A computed tomographic image study on the thickness of the infrazygomatic crest of the maxilla and its clinical implications for miniscrew insertion

Eric J. W. Liou,<sup>a</sup> Po-Hsun Chen,<sup>b</sup> Yu-Chih Wang,<sup>b</sup> and James Chen-Yi Lin<sup>b</sup>

Taipei, Taiwan

**Introduction:** The purpose of this study was to measure the thickness of the infrazygomatic (IZ) crest above the maxillary first molar at different angles and positions to the maxillary occlusal plane. These measurements were then used to derive clinical implications and guidance for inserting miniscrews in the IZ crest without injuring the mesiobuccal root of the maxillary first molar. **Methods:** Computed tomographic images of 16 adults were used. For each subject, on the coronal slice of the computed tomographic image containing the IZ crest and mesiobuccal root of the maxillary first molar, the IZ crest thickness and the miniscrew insertion position were measured by postulating that the miniscrew would be inserted at each 5° increment from 40° to 75° to the maxillary occlusal plane. **Results:** The IZ crest thickness above the maxillary first molar ranged from  $5.2 \pm 1.1$  mm to  $8.8 \pm 2.3$  mm, measured at 40° to 75° to the maxillary occlusal plane and 13 to 17 mm above the maxillary occlusal plane. **Conclusions:** By adopting 6 mm as the minimal IZ crest thickness for sustaining a miniscrew well throughout treatment and avoiding injury to the mesiobuccal root of the maxillary first molar, the clinical implication for miniscrew placement in the IZ crest of an adult is to insert it 14 to 16 mm above the maxillary occlusal plane and the maxillary first molar at an angle of 55° to 70° to the maxillary occlusal plane. (Am J Orthod Dentofacial Orthop 2007;131:352-6)

The infrazygomatic (IZ) crest is a placement site in the maxilla for orthodontic miniscrews or miniplates. It has been used successfully to provide skeletal anchorage for maxillary canine retraction, anterior retraction, en-masse anterior retraction, and intrusion of the maxillary posterior teeth.<sup>1-9</sup>

Anatomically, the IZ crest is a pillar of cortical bone at the zygomatic process of the maxilla (Fig 1). Clinically, it is a palpable bony ridge running along the curvature between the alveolar and zygomatic processes of the maxilla. In younger subjects, it is between the maxillary second premolar and first molar, whereas it is above the maxillary first molar in adults. A serious complication during miniscrew insertion in the IZ crest of adults is injury to the mesiobuccal root of the maxillary first molar. The maxillary interdental sites for insertion of miniscrews were shown radiographi-

cally.<sup>10-13</sup> It is recommended to insert miniscrews in higher rather than lower positions, such as midroot, at or beyond the root apex where interseptal bone is thicker and there is less chance of root injury.

However, without injuring the mesiobuccal root of the maxillary first molar, the appropriate sites and angles for insertion of the miniscrew in the IZ crest have not yet been well documented. The purposes of this computed tomographic (CT) image study were to show the thickness of the IZ crest above the maxillary first molar and the biting depth of a miniscrew in the IZ crest at different angles and positions to the maxillary occlusal plane, and to derive clinical implications for miniscrew insertion in the IZ crest without injuring the mesiobuccal root of the maxillary first molar.

## MATERIALS AND METHODS

The CT images of 16 adults (6 women, 10 men; average age,  $27.0 \pm 5.2$  years) with no craniofacial anomalies or systemic diseases were randomly selected from the database of the craniofacial CT imaging library of Chang Gung Memorial Hospital, Taipei, Taiwan. The machine was a spiral CT scanner (SOMATOM Sensation 16, Siemens, Munich, Germany). The CT images were formatted into

From the Department of Orthodontics and Craniofacial Dentistry, Chang Gung Memorial Hospital, Taipei, Taiwan.

<sup>a</sup>Assistant professor.

<sup>b</sup>Attending staff.

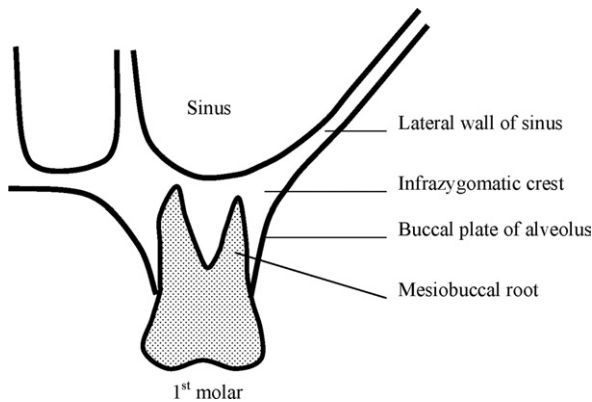
Reprint requests to: Dr Eric J. W. Liou, Chang Gung Memorial Hospital, 199 Tung-Hwa North, Taipai, 105, Taiwan; e-mail, lioueric@ms19.hinet.net.

Submitted, October 2004; revised and accepted, April 2005.

0889-5406/\$32.00

Copyright © 2007 by the American Association of Orthodontists.

doi:10.1016/j.ajodo.2005.04.044



**Fig 1.** Schematic illustration of IZ crest above mesio-buccal root of maxillary first molar.

standard dicom and reconstructed into continuous slices at 1-mm thickness each.

We used Analyze (Mayo Clinic, Rochester, Minn) for the CT image analyses. The images were first adjusted to the tissue threshold to extract the soft tissue. Then the images of the hard tissue were displayed simultaneously with their coronal, axial, and sagittal slices so that the IZ crest containing the mesio-buccal root of the maxillary first molar could be accurately located (Fig 2).

On the selected coronal slice, reference lines and points were established for measurements of lateral wall thickness of the maxillary sinus and IZ crest thickness (Fig 3). The first reference line was the maxillary occlusal plane, a plane between the mesio-buccal cusps of both maxillary first molars. The second reference line was the tangent line to the buccal surface of the mesio-buccal root of the maxillary first molar. The intersection point of this tangent line and the floor of the maxillary sinus was the sinus point (S point).

Through S point, another 8 reference lines were established at increments of 5°, from 40° to 75°, to the maxillary occlusal plane (Fig 3). These 8 reference lines also were the postulated miniscrew insertion angles. The intersections between these reference lines and the lateral surface of the IZ crest were points B1 to B8. The length between S point and B1 to B8, respectively, was IZ crest thickness. The perpendicular distances from B1 to B8, respectively, to the maxillary occlusal plane were the postulated miniscrew insertion positions. The lateral wall thickness of the maxillary sinus, 5 mm above S point, was also measured.

For each measurement, both the left and right sides were measured. They were compared with the Student *t* test for differences ( $P < .05$ ). The lateral wall thickness of the maxillary sinus and the IZ crest thickness at

various miniscrew insertion angles were compared with analysis of variance (ANOVA) ( $P < .05$ ).

## RESULTS

The right and left measurements of lateral wall thickness of the maxillary sinus or the IZ crest thickness at each miniscrew insertion angle were not significantly different ( $P > .05$ ). The right and left measurements were therefore pooled.

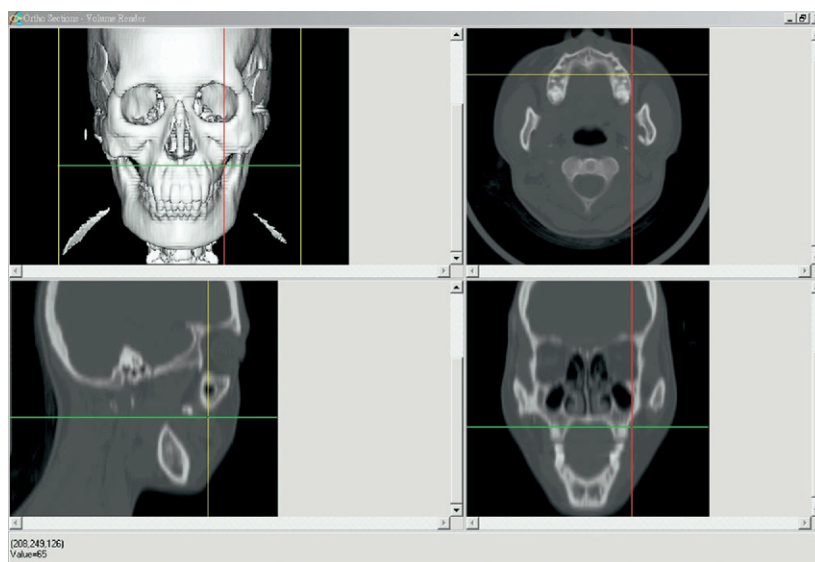
The IZ crest thickness varied with the postulated miniscrew insertion angles. The greater the postulated miniscrew insertion angle, the thicker the IZ crest would be (Fig 4, A). The IZ crest thickness was  $5.2 \pm 1.1$  mm when the postulated miniscrew insertion angle was 40° to the maxillary occlusal plane, and it was  $8.8 \pm 2.3$  mm with a postulated insertion angle of 75° to the maxillary occlusal plane (Table I). The IZ crest thickness at each postulated miniscrew insertion angle was significantly greater than the lateral wall thickness of the maxillary sinus ( $2.9 \pm 0.9$  mm) (Table I).

The miniscrew insertion position also varied with the postulated miniscrew insertion angle. The smaller the postulated miniscrew insertion angle, the higher the miniscrew insertion position relative to the maxillary occlusal plane (Fig 4, B). The miniscrew insertion position was  $17.0 \pm 3.7$  mm above the maxillary occlusal plane when the postulated insertion angle was 40° to the maxillary occlusal plane, and it was  $12.8 \pm 4.2$  mm above the maxillary occlusal plane when the postulated insertion angle was 75° to the maxillary occlusal plane (Table II).

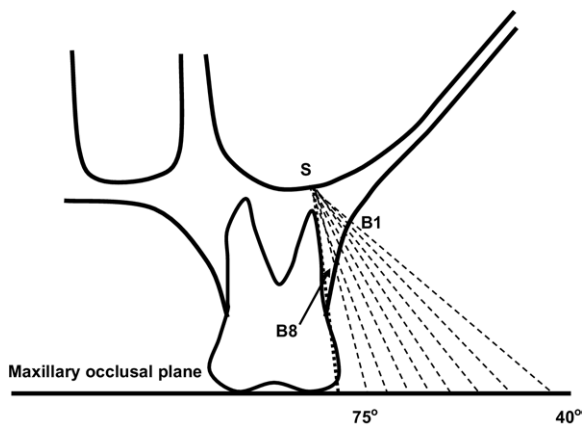
## DISCUSSION

The IZ crest above the maxillary first molar, as shown in this study, was significantly thicker than the lateral wall of the maxillary sinus. As an insertion site for orthodontic skeletal anchorage, the IZ crest is usually used for a single miniscrew because of its thicker bone,<sup>2,4,7-9</sup> whereas the lateral wall of the maxillary sinus is used for miniplates with several miniscrews because of its thinner wall.<sup>3,5,6</sup> A thicker bone allows greater miniscrew biting depth, more osseous contact, and better primary stability of the miniscrew.<sup>14</sup> The IZ crest has 2 cortical plates—the buccal cortical plate and the sinus floor. This anatomic advantage allows for bicortical fixation and possibly contributes to better primary stability of the miniscrew.

The IZ crest thickness is also the miniscrew biting depth when the postulated miniscrew is inserted through and in the IZ crest. To obtain a 5- to 9-mm miniscrew biting depth without injuring the mesio-buccal root of the maxillary first molar, the miniscrew insertion position and the postulated miniscrew inser-



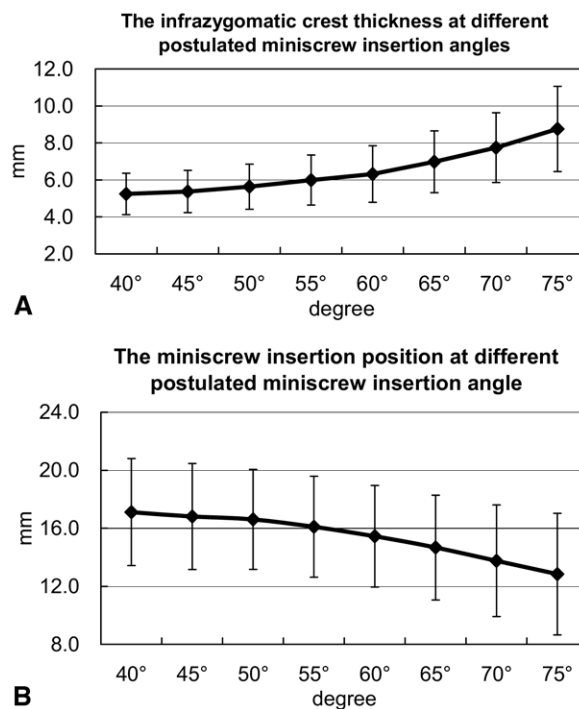
**Fig 2.** CT images displayed simultaneously with coronal, axial, and sagittal slices so that IZ crest containing mesiobuccal root of maxillary first molar can be accurately located.



**Fig 3.** Reference points and lines for linear measurements.

tion angle ranged from 17 mm above and 40° to the maxillary occlusal plane to 14 mm above and 75° to the maxillary occlusal plane. However, the 75° postulated miniscrew insertion angle and position are technically difficult because of the acute insertion angle between the miniscrew and the IZ crest. This causes slippage of the miniscrew and bone stripping. At this postulated insertion angle and position, the miniscrew would be near the mesiobuccal root of the maxillary first molar. This might cause a risk of root injury, especially when the miniscrew insertion is slightly deviated.

In contrast, the 40° postulated miniscrew insertion angle and position are technically easier, with no miniscrew slippage, bone stripping, or root injury, but it



**Fig 4. A,** Mean IZ crest thickness with 1 SD at various postulated miniscrew insertion angles; **B,** mean miniscrew insertion position with 1 SD at various postulated miniscrew insertion angles.

would have a shallower biting depth and also a greater chance of alveolar or buccal mucosa irritation. The emergence of a miniscrew head at the alveolar mucosa frequently causes soft-tissue embedment, irritation, or

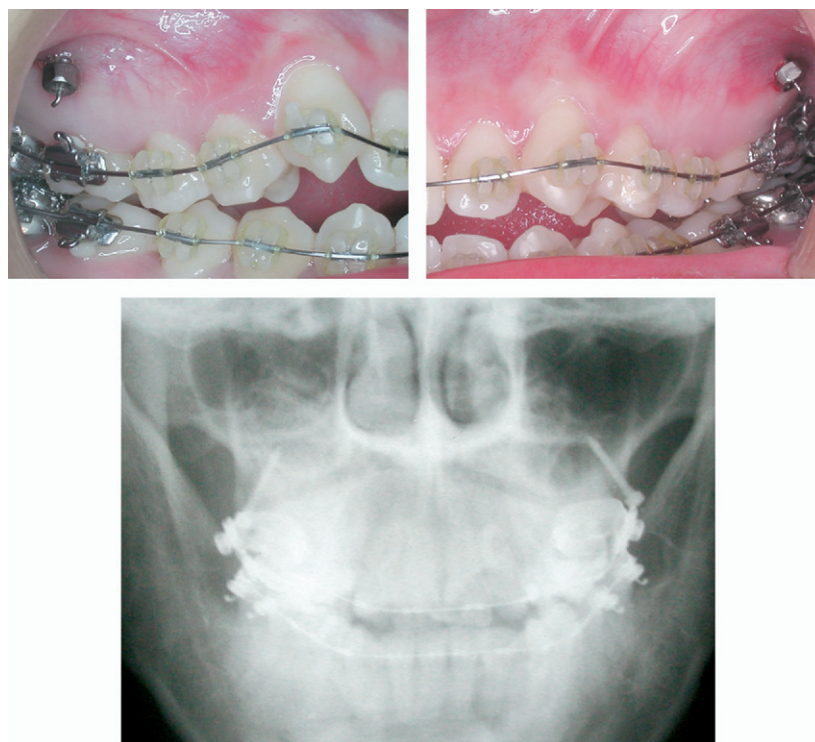
**Table I.** Descriptive and statistical analyses of lateral wall thickness of maxillary sinus and IZ crest thickness (mean ± SD) at 5° increments to maxillary occlusal plane

IZ crest thickness (mm)								Sinus wall thickness
40°	45°	50°	55°	60°	65°	70°	75°	
5.2 ± 1.1	5.4 ± 1.1	5.6 ± 1.2	6.0 ± 1.4	6.3 ± 1.5	7.0 ± 1.7	7.7 ± 1.9	8.8 ± 2.3	2.9 ± 0.9*

\*P < .001 (ANOVA).

**Table II.** Descriptive analysis of miniscrew insertion position (mean ± SD) (perpendicular distance to maxillary occlusal plane) at increments of 5° to maxillary occlusal plane

Miniscrew insertion position (mm)							
40°	45°	50°	55°	60°	65°	70°	75°
17.1 ± 3.7	16.8 ± 3.7	16.6 ± 3.4	16.1 ± 3.5	15.4 ± 3.5	14.7 ± 3.6	13.8 ± 3.8	12.8 ± 4.2



**Fig 5.** Clinical implications for miniscrew insertion in IZ crest of adults are to insert miniscrew 14-16 mm above maxillary occlusal plane and maxillary first molar, at angle of 55°-70° to maxillary occlusal plane.

infection around a miniscrew.<sup>2,15</sup> To prevent these problems, it is recommended to place a miniscrew at the keratinized gingiva or the mucogingival junction.<sup>10,15</sup> The 40° postulated miniscrew insertion position is 17 mm above the maxillary occlusal plane, in the alveolar mucosa but not the attached gingival.<sup>16</sup> Although the miniscrew insertion position is not neces-

sarily the same as its soft-tissue emergence, at the 40° postulated insertion angle and position, the miniscrew could still emerge at the alveolar mucosa and cause soft-tissue irritation.

Greater miniscrew-bone contact has better primary stability.<sup>14</sup> Without injuring any vital structure, the miniscrew should be inserted as deep as possible to

increase its biting depth and therefore miniscrew-bone contact. In an experimental study on the IZ crest of 4 adult *Macaca fascicularis* monkeys, Melsen and Costa<sup>4</sup> reported that, with 50 g of immediate load, a 6-mm miniscrew biting depth sustained all 8 miniscrews (8 by 2 mm) during the 6-month experimental period. In another study on the reduced maxillary height of the edentulous ridges of 2 dogs, Wehrbein et al<sup>17</sup> reported that, after 8 weeks of healing and then 2N of orthodontic loading for 6 months, a 6-mm miniscrew biting depth sustained all 4 miniscrews (10 mm in length) throughout the experimental period. According to Misch<sup>18</sup> and Misch and Kircos,<sup>19</sup> bone density of the IZ crest is greater than that of the maxillary alveolar ridge (D2/D3 vs D3/D4).<sup>20,21</sup> According to these studies,<sup>4,17-21</sup> it seems that, in adults, a 6-mm miniscrew biting depth in the IZ crest is sufficient for sustaining the miniscrew throughout the loading period, although more experimental and clinical studies are needed.

As shown in this CT image study, the postulated miniscrew insertion angle should be greater than 55°, and the insertion position should be less than 16 mm above the maxillary occlusal plane so that the miniscrew biting depth is not less than 6 mm. However, as mentioned earlier, the 75° postulated miniscrew insertion angle and position have technical problems, and there is a risk of root injury during miniscrew insertion. Therefore, the proper miniscrew insertion area in the IZ crest is above the maxillary first molar and 14 to 16 mm above the maxillary occlusal plane, and the insertion angle should be 55° to 70° to the maxillary occlusal plane (Fig 5).

## CONCLUSIONS

Bone thickness of the IZ crest above the maxillary first molar is 5 to 9 mm, when it is measured at 40° to 75° to the maxillary occlusal plane and 13 to 17 mm above the maxillary occlusal plane. By adopting 6 mm as the minimum IZ crest thickness for sustaining a miniscrew well throughout treatment and avoiding bone stripping, injury to the mesiobuccal root of the maxillary first molar, and alveolar/buccal mucosa irritation, the clinical implication for miniscrew insertion in the IZ crest of adults is 14 to 16 mm above the maxillary occlusal plane and the maxillary first molar, and at an angle of 55° to 70° to the maxillary occlusal plane.

## REFERENCES

- Melsen B, Peterson JK, Costa A. Zygoma ligatures: an alternative form of maxillary anchorage. *J Clin Orthod* 1998;32:154-8.
- Costa A, Raffaini M, Melsen B. Miniscrews as orthodontic anchorage: a preliminary report. *Int J Adult Orthod Orthognath Surg* 1998;13:201-9.
- Umemori M, Sugawara J, Mitani H, Nagasaka H, Kawamura H. Skeletal anchorage system for open-bite correction. *Am J Orthod Dentofacial Orthop* 1999;115:166-74.
- Melsen B, Costa A. Immediate loading of implants used for orthodontic anchorage. *Clin Orthod Res* 2000;3:23-8.
- Clerck H, Geerinckx V, Siciliano S. The zygoma anchorage system. *J Clin Orthod* 2002;36:455-9.
- Chung KR, Kim YS, Linton LJ, Lee YJ. The miniplate with tube for skeletal anchorage system. *J Clin Orthod* 2002;36:407-12.
- Lin JCY, Liou EJ. A new bone screw for orthodontic anchorage. *J Clin Orthod* 2003;37:676-82.
- Liou EJ, Pai BC, Lin JCY. Do miniscrews remain stationary under orthodontic forces? *Am J Orthod Dentofacial Orthop* 2004;126:42-7.
- Kuroda S, Katayama A, Takano-Yamamoto T. Severe anterior open-bite case treated using titanium screw anchorage. *Angle Orthod* 2004;74:558-67.
- Schnelle MA, Beck FM, Jaynes RM, Huja SS. A radiographic evaluation of the availability of bone for placement of miniscrews. *Angle Orthod* 2004;74:830-5.
- Kanomi R. Mini-implant for orthodontic anchorage. *J Clin Orthod* 1997;31:763-7.
- Kanomi R, Takada K. Application of titanium mini-implant system for orthodontic anchorage. In: Davidovitch Z, Mah J, editors. *Biological mechanics of tooth movement and craniofacial adaptation*. Boston: Harvard Society for the Advancement of Orthodontics; 2000. p. 253-8.
- Park HS, Kyung HM, Sung JH. A simple method of molar uprighting with micro-implant anchorage. *J Clin Orthod* 2002;36:592-6.
- Deguchi T, Takano-Yamamoto T, Kanomi R, Hartsfield JK Jr, Roberts WE, Garetto LP. The use of small titanium screws for orthodontic anchorage. *J Dent Res* 2003;82:377-81.
- Cheng SJ, Tseng IY, Lee JJ, Kok SH. A prospective study of the risk factors associated with failure of mini-implants used for orthodontic anchorage. *Int J Oral Maxillofac Implants* 2004;19:100-6.
- Lang NP, Loe H. The relationship between the width of keratinized gingiva and gingival health. *J Periodontol* 1972;43:623-7.
- Wehrbein H, Glatzmaier J, Yildirim M. Orthodontic anchorage capacity of short titanium screw implants in the maxilla. An experimental study in the dog. *Clin Oral Implants Res* 1997;8:131-41.
- Misch CE. Bone character: second vital implant criterion. *Dent Today* 1988;7:39-40.
- Misch CE, Kircos LT. Diagnostic imaging and techniques. In: Misch CE, editor. *Contemporary implant dentistry*. 2nd ed. St Louis: Mosby; 1999. p. 73-87.
- Lin JC, Liou EJ. A new bone screw for orthodontic anchorage. *J Clin Orthod* 2003;37:676-81.
- Lin JC, Liou EJ, Yeh CL. Intrusion of overerupted maxillary molars with miniscrew anchorage. *J Clin Orthod* 2006;40:378-83.